Characterization of the Göttingen Minipig for Cerebrospinal Administration and CSF collection

Julie Douville, Frederick Emond, Claudia Foucault, Giuseppina Iacono, Jean-François Lafond, René St-Jacques, Christine Copeman
Charles River Laboratories, Montreal, Quebec, Canada

charles river

1 INTRODUCTION

The minipig is considered an excellent surrogate nonrodent model for use on safety assessment studies given its many similarities with human (skin, eye, heart, lung, etc). It has been used extensively with the dermal, ocular, intravenous and oral routes of administration, as well as on safety pharmacology studies. However, less work has been conducted via the cerebrospinal route. Given that many neurodegenerative diseases represent a large pool of unmet needs, and that an increasing number of therapeutic molecules being developed are biologics that cannot cross the blood-brain barrier, we investigated the suitability of the swine for neurological safety assessment studies.

Following the development of a surgical implantation approach of a lumbar intrathecal catheter, we mimicked dose administration twice weekly for 14 days using saline, and monitored clinical signs, body weight, food intake, clinical pathology and conducted histopathology of the spinal cord and brain. Cerebrospinal fluid (CSF) was also obtained from conscious animals via the catheter system or by direct puncture at the lumbar level from non catheterized animals.
.

2 MATERIALS AND METHODS

Four 7 to 8 month old male Göttingen minipigs weighing 8 to 17.2 kg obtained from Marshall BioResources, North Rose, NY, were used for the surgical approach. An additional 12 animals (males and females) were used to further refine the direct puncture approach. They were fed a standard certified swine diet twice daily, and were housed in stainless steel cages equipped with a vinyl coated mesh floor and an automatic watering system. The animal room was maintained between 17 to 23°C and 30 to 70% RH, with a 12-hour light/dark cycle.

Surgery

Selected animals (4) were prepared for surgery. They received a pre-anesthetic cocktail, and anesthesia was maintained using oxygen and isoflurane gas following intubation; all animals received a standard protocol of antibiotics and multi-modal analgesics. The dorsal lumbar area was shaved, cleaned and the animal was placed in ventral recumbency. The skin at the L5 level was incised and a microlaminectomy followed by a durotomy were performed; a polyurethane-based catheter was then inserted in the intrathecal space. The catheter was anchored to the dura and a subcutaneous pocket was created slightly cranial and lateral to the surgical site, and an access port was fixed to the muscle; the catheter was then connected to the access port. The surgical site was flushed with saline and the skin was closed with interrupted subcutaneous sutures and cruciate sutures.

2 MATERIALS AND METHODS (continued)

In-Life Evaluations

Following recovery from the surgical procedures, 3 animals were closely monitored for signs of discomfort including any signs of behavior or gait changes at least twice daily for 14 days. Prior to euthanasia, animals were weighed and samples were collected for clinical pathology investigations.

Direct Puncture Approach

For dose administration and CSF collection by direct puncture, animals were anesthetized with a standard cocktail, placed in lateral recumbency and the cisterna magna or lumbar area was aseptically prepared. A spinal needle was slowly inserted until CSF flow was observed in the hub. The CSF was analysed for white blood cell counts, red blood cell count, and clinical chemistry parameters.

Post-Mortem Evaluations

At the end of the observation period, animals were euthanized, sections of the spinal cord and of the brain were prepared and tissues were embedded in paraffin and stained with H&E. Detailed histopathology was conducted to characterize any procedure-related effects.

3 RESULTS

All surgeries were considered successful with the exception of one for which insertion of the catheter in the intrathecal space could not be achieved; this animal was euthanized at the end of the surgical procedure. The remaining 3 animals fully recovered from implantation. A contrasting agent (omnipaque) was injected and fluoroscopy of dorsal views were taken to confirm placement in the intrathecal space. Catheter patency was confirmed both for administration and CSF collection. For dosing and collection, the animal was restrained on a sling, the access port site was shaved and cleaned, and a huber needle was inserted in the port.

There were no effects on body weights or food intake. Clinical pathology evaluation including a standard pannel of hematology and biochemistry parameters revealed no significant impact of the surgical procedures or bi-weekly saline administration, as shown in Figure 1.

CSF collections under anesthesia were successful from the lumbar level (between L4 and L6). Collections from the cisterna magna via direct puncture proved to be more challenging and CSF was obtained in 5 out of 9 trials. Quality of the CSF samples was evaluated including clinical pathology parameters evaluations of the lumbar samples and results were compared to other species (Figure 2).

Histopathological evaluation showed no evidence of any inflammatory reaction or degenerative process in the spinal cord (Figure 3).

Figure 1: Blood clinical pathology results

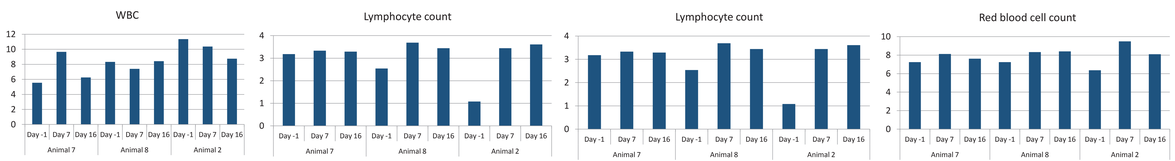

Figure 2: CSF clinical pathology results

	RBC	EOS	LYMPH	MACRO	MONO	NEUT	NUC CELL	PHOS	K	PROT	Na	ALB	CA	Cl	GLUC
*NHP M	171,6	6,20	25,3	48,9	0	19,6	4,60	1,45	2,80	0,15	154,1	55,7	4,70	130,8	57,7
*NHP F	192,4	3,27	30,1	51,7	0	15,0	2,75	1,53	2,75	0,17	154,5	61,5	4,98	130,1	58,4
+RAT M	-	0,73	62,7	8,35	10,76	17,5	2,20	-	-	-	-	-	-	-	-
+RAT F	-	0,57	52,9	6,67	26,76	13,2	2,56	-	-	-	-	-	-	-	-
#PIG M/F	**168,4**	**-**	**-**	**-**	**-**	**-**	**13,10**	**1,33**	**3,10**	**0,19**	**150,9**	**18,0**	**5,20**	**125,6**	**51,1**

M = Males; F = Females
* : values derived from 9 to 18 animals/sex
+ : values derived from 7 to 10 animals/sex
# : values derived from 7 animals

Figure 3: Spinal cord stained with H&E

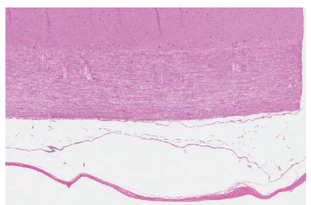

4 CONCLUSIONS

Overall, implantation of a catheter for intrathecal administration and CSF collection in the minipig resulted in data comparable to historical data from other species similarly implanted at the lumbar level. There was no procedural-related findings at the site of the catheter implantation. CSF collection from the lumbar site was successful and reproducible, and clinical pathology parameters evaluated were comparable to values obtained in other species. These results show that the minipig is a suitable model for cerebrospinal delivery studies and CSF sampling.

5 Acknowledgements

The authors would like to thank the technical and scientific team at Charles River Montreal for their contribution.